

Elements of the Pre-Operative Workup, Case Examples

Alan T. Villavicencio, MD, and Sigita Burneikiene, MD

Boulder Neurosurgical Associates, Boulder, Colorado, USA

ABSTRACT

Spinal cord stimulation (SCS) is a well-recognized method of treating a variety of chronic neuropathic conditions that are refractory to conservative management. One of the most challenging aspects of this technique is proper patient selection. In this study we reviewed available knowledge, differential diagnosis, and strategies utilized for the management of patients who were considered for a neurostimulation procedure. Clinical and neurological evaluation, complete diagnostic workup, a behavioral assessment, and a screening trial are all essential to determine a patient's suitability for SCS implantation. A correct diagnosis and proper indications will help to achieve optimal treatment results and improve quality of life for a considerable number of patients suffering from intractable pain.

Key Words. Spinal Cord Stimulation; Neuromodulation; Patient Selection; Pre-Operative Workup

Spinal cord stimulation (SCS) is a well-recognized method of managing a variety of chronic neuropathic conditions that are refractory to conservative management. One of the most challenging aspects of this technique is proper patient selection. Poor patient selection is thought to be the main reason for many of the suboptimal long-term results reported in the 1970s [1,2]. In addition to technical improvements in the implanted hardware, improved methods of evaluating patient psychological problems (such as drug dependence and secondary gain issues) have led to better rates of long-term efficacy ranging from 60% to 80% [1,3]. Indications for spinal cord neuromodulation include peripheral deafferentation pain or chronic nonmalignant pain of neuropathic origin [4] that is amendable to stimulation coverage. Failed back surgery syndrome (FBSS), arachnoiditis, complex regional pain syndrome (CRPS), radiculopathy, phantom limb syndrome, and peripheral neuropathy are the most frequently treated conditions in the United States with this technique [5,6]. The underlying etiology of the

pain disorder should be established prior to device implantation. Central deafferentation pain syndromes that are associated with a lesion of the central nervous system (e.g., stroke, spinal cord injury) do not tend to respond as well to SCS. Patients suffering from nociceptive or somatic pain (e.g., cancer pain) that results from nerve irritation, pain in multiple sites, or pain with changing patterns, sometimes respond better to intrathecal drug administration.

Permanent implantation of spinal cord stimulator leads is considered only after multidisciplinary conservative therapies have failed and further neural decompressive surgeries are not indicated. The treating physician should critically evaluate the underlying diagnosis. A detailed history and comprehensive physical examination is essential. Patients are asked to describe the nature and severity of their pain and indicate its onset and duration. Neuropathic pain can be described using a wide variety of terms, which include burning, constrictive, tearing, shooting, or tingling type of pain. Individual pain evaluation remains subjective. Various pain assessment tools (visual or numeric) are used to rate pain. These include the McGill-Melzack Pain Questionnaire (Figure 1), various pain assessment maps (Figure 2), a five-point pain scale (Figure 3), or the Visual Analog Scale (VAS) (Figure 2). Radiating pain tends to be

Reprint requests to: Alan T. Villavicencio, MD, Boulder Neurosurgical Associates, 1155 Alpine Avenue, Suite 320, Boulder, CO 80304, USA. Tel: 303-998-0004; Fax: 303-998-0007; E-mail: atv@bnasurg.com.

MCGILL PAIN QUESTIONNAIRE

RONALD MELZACK

Patient's Name _____ Date _____ Time _____ am/pm

PRI: S _____ A _____ E _____ M _____ PRI(T) _____ PPI _____
 (1-10) (11-15) (16) (17-20) (1-20)

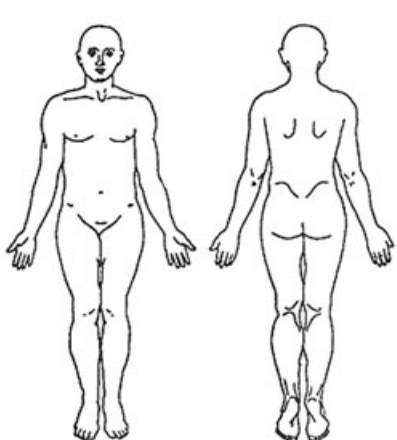
<table border="1" style="width: 100%; border-collapse: collapse;"> <tr> <td style="width: 50%; vertical-align: top;"> <p>1 FLICKERING QUIVERING PULSING THROBBING BEATING POUNDING</p> <p>2 JUMPING FLASHING SHOOTING</p> <p>3 PRICKING BORING DRILLING STABBING LANCINATING</p> <p>4 SHARP CUTTING LACERATING</p> <p>5 PINCHING PRESSING GNAWING CRAMPING CRUSHING</p> <p>6 TUGGING PULLING WRENCHING</p> <p>7 HOT BURNING SCALDING SEARING</p> <p>8 TINGLING ITCHY SMARTING STINGING</p> <p>9 DULL SORE HURTING ACHING HEAVY</p> <p>10 TENDER TAUT RASPING SPLITTING</p> </td> <td style="width: 50%; vertical-align: top;"> <p>11 TIRING EXHAUSTING</p> <p>12 SICKENING SUFFOCATING</p> <p>13 FEARFUL FRIGHTFUL TERRIFYING</p> <p>14 PUNISHING GRUELLING CRUEL VICIOUS KILLING</p> <p>15 WRETCHED BLINDING</p> <p>16 ANNOYING TROUBLESOME MISERABLE INTENSE UNBEARABLE</p> <p>17 SPREADING RADIATING PENETRATING PIERCING</p> <p>18 TIGHT NUMB DRAWING SQUEEZING TEARING</p> <p>19 COOL COLD FREEZING</p> <p>20 NAGGING NAUSEATING AGONIZING DREADFUL TORTURING</p> <p style="text-align: center;">PPI</p> <p>0 NO PAIN 1 MILD 2 DISCOMFORTING 3 DISTRESSING 4 HORRIBLE 5 EXCRUCIATING</p> </td> </tr> </table>	<p>1 FLICKERING QUIVERING PULSING THROBBING BEATING POUNDING</p> <p>2 JUMPING FLASHING SHOOTING</p> <p>3 PRICKING BORING DRILLING STABBING LANCINATING</p> <p>4 SHARP CUTTING LACERATING</p> <p>5 PINCHING PRESSING GNAWING CRAMPING CRUSHING</p> <p>6 TUGGING PULLING WRENCHING</p> <p>7 HOT BURNING SCALDING SEARING</p> <p>8 TINGLING ITCHY SMARTING STINGING</p> <p>9 DULL SORE HURTING ACHING HEAVY</p> <p>10 TENDER TAUT RASPING SPLITTING</p>	<p>11 TIRING EXHAUSTING</p> <p>12 SICKENING SUFFOCATING</p> <p>13 FEARFUL FRIGHTFUL TERRIFYING</p> <p>14 PUNISHING GRUELLING CRUEL VICIOUS KILLING</p> <p>15 WRETCHED BLINDING</p> <p>16 ANNOYING TROUBLESOME MISERABLE INTENSE UNBEARABLE</p> <p>17 SPREADING RADIATING PENETRATING PIERCING</p> <p>18 TIGHT NUMB DRAWING SQUEEZING TEARING</p> <p>19 COOL COLD FREEZING</p> <p>20 NAGGING NAUSEATING AGONIZING DREADFUL TORTURING</p> <p style="text-align: center;">PPI</p> <p>0 NO PAIN 1 MILD 2 DISCOMFORTING 3 DISTRESSING 4 HORRIBLE 5 EXCRUCIATING</p>	<table border="1" style="width: 100%; border-collapse: collapse;"> <tr> <td style="width: 33%;">BRIEF _____</td> <td style="width: 33%;">RHYTHMIC _____</td> <td style="width: 33%;">CONTINUOUS _____</td> </tr> <tr> <td>MOMENTARY _____</td> <td>PERIODIC _____</td> <td>STEADY _____</td> </tr> <tr> <td>TRANSIENT _____</td> <td>INTERMITTENT _____</td> <td>CONSTANT _____</td> </tr> </table> <div style="text-align: center; margin-top: 20px;">  </div> <div style="text-align: center; margin-top: 10px;"> <table border="1" style="margin: auto;"> <tr> <td>E = EXTERNAL</td> </tr> <tr> <td>I = INTERNAL</td> </tr> </table> </div> <div style="border: 1px solid black; padding: 10px; margin-top: 20px;"> <p><u>COMMENTS:</u></p> </div> <p style="text-align: right; font-size: small;">© R. MELZACK, 1975</p>	BRIEF _____	RHYTHMIC _____	CONTINUOUS _____	MOMENTARY _____	PERIODIC _____	STEADY _____	TRANSIENT _____	INTERMITTENT _____	CONSTANT _____	E = EXTERNAL	I = INTERNAL
<p>1 FLICKERING QUIVERING PULSING THROBBING BEATING POUNDING</p> <p>2 JUMPING FLASHING SHOOTING</p> <p>3 PRICKING BORING DRILLING STABBING LANCINATING</p> <p>4 SHARP CUTTING LACERATING</p> <p>5 PINCHING PRESSING GNAWING CRAMPING CRUSHING</p> <p>6 TUGGING PULLING WRENCHING</p> <p>7 HOT BURNING SCALDING SEARING</p> <p>8 TINGLING ITCHY SMARTING STINGING</p> <p>9 DULL SORE HURTING ACHING HEAVY</p> <p>10 TENDER TAUT RASPING SPLITTING</p>	<p>11 TIRING EXHAUSTING</p> <p>12 SICKENING SUFFOCATING</p> <p>13 FEARFUL FRIGHTFUL TERRIFYING</p> <p>14 PUNISHING GRUELLING CRUEL VICIOUS KILLING</p> <p>15 WRETCHED BLINDING</p> <p>16 ANNOYING TROUBLESOME MISERABLE INTENSE UNBEARABLE</p> <p>17 SPREADING RADIATING PENETRATING PIERCING</p> <p>18 TIGHT NUMB DRAWING SQUEEZING TEARING</p> <p>19 COOL COLD FREEZING</p> <p>20 NAGGING NAUSEATING AGONIZING DREADFUL TORTURING</p> <p style="text-align: center;">PPI</p> <p>0 NO PAIN 1 MILD 2 DISCOMFORTING 3 DISTRESSING 4 HORRIBLE 5 EXCRUCIATING</p>													
BRIEF _____	RHYTHMIC _____	CONTINUOUS _____												
MOMENTARY _____	PERIODIC _____	STEADY _____												
TRANSIENT _____	INTERMITTENT _____	CONSTANT _____												
E = EXTERNAL														
I = INTERNAL														

Figure 1 McGill-Melzack Pain Questionnaire.

Pain Drawing

Name: _____ Age: _____ Date: _____

WHERE IS YOUR PAIN NOW:
 Mark areas on your body where you feel the described sensations. Use the appropriate symbol. Mark areas of radiation. Include all affected areas.

SEMILOGY CHART

ANTERIOR

POSTERIOR

Ache: ~~~~~

Numbness: oooooo

Pins & Needles: +++++

Burning: xxxxxx

Radiating Pain: //////////////

Neck Pain _____ %

Arm Pain _____ %

Back Pain _____ %

Leg Pain _____ %

Total = _____ %

Figure 2 Pain assessment map and diagram used in the clinic to allow for patients to color in their symptoms onto the relevant area of their body. Also included is a visual analog scale to allow patients to grade their pain on a scale from 0 to 10.

HOW BAD IS YOUR PAIN NOW? (Please mark on the line)

Neck Pain

No Pain 0-----1-----2-----3-----4-----5-----6-----7-----8-----9-----10 Worst Pain

Back Pain

No Pain 0-----1-----2-----3-----4-----5-----6-----7-----8-----9-----10 Worst pain

more effectively treated with neurostimulation as apposed to trunk, lateral, and midline pain components. Neurostimulation has had limited success in alleviating very severe excruciating pain (80–90 on VAS), evoked, paroxysmal or shooting pain, and pain related to posture changes [7]. Neurostimulation is more effective if the disease progression is static. Spatial characteristics of pain and distribution patterns dictate the level at which the SCS lead(s) should be placed.

It is essential to correlate clinical features of the pain syndrome with the neurological status. A detailed neurological examination is performed with sensory and motor system assessment, paying particular attention to the sensory system. A sensory examination for patients with neuropathic pain is performed to establish whether a stimulus is perceived as normal, hypoesthesia, or hyperesthesia. Major hypoesthesia may indicate a loss of large-fiber dorsal column (DC) functions. Hyperesthesia is often observed in patients suffering from neuropathic pain with the typical sensation

disturbances being allodynia (painful reaction to usually nonpainful stimulus) and hyperalgesia (exaggerated pain response). These symptoms are considered to be diagnostic for a dysfunctional sensory nervous system [8]. Neurostimulation is more effective if a patient has a single unilateral or mononeuropathic—radicular pain site. In addition, a motor system examination could reveal weakness, apraxia, or neglect symptoms.

Neurostimulation should not be considered for a symptomatic treatment of a patient with a surgically treatable lesion. Likewise, candidates for

5-Point Pain Scale	
1	No Pain
2	Mild Pain
3	Moderate Pain
4	Severe Pain
5	Overwhelming Pain (the worst pain you can imagine)

Figure 3 Five-point scale that allows patients to grade their pain.

neurostimulation should not demonstrate progressive neurological dysfunction (e.g., weakness, bladder, or bowel dysfunction) related to a structural lesion. Patients presenting with such symptomatology should be thoroughly investigated for other underlying causes of their problems.

Diagnosis of CRPS is almost exclusively based on neurological examination and very distinct symptoms reported by the patient. Patients often complain of deep, sharp, sensitive, and/or hot pain typically located in a distal part of the upper or lower extremity accompanied by edema, sweating, and skin temperature and color changes [9]. Sensory symptoms also include hyperalgesia and/or allodynia on clinical examination. Motor dysfunction is frequently described as weakness or a decreased range of motion. Although some authors suggest using various diagnostic tests to make a diagnosis such as plain radiographs, bone scintigraphy, or thermography, none of these have been found to be of any consistent proven value. This is with the exception of electrophysiologic studies. Electromyography (EMG) can sometimes confirm the presence of large-fiber peripheral nerve injury for the diagnosis of CRPS type II. Peripheral nerve conduction and EMG studies can also be utilized to distinguish different types of more common peripheral mono- or polyneuropathies. As mentioned, this is especially useful in assessing large-fiber DC function, as its preservation is one of the prerequisites for inducing paresthesias [7].

Imaging studies are critical in identifying anatomic abnormalities or conditions that could be corrected surgically instead of or in addition to SCS placement (case examples 1, 2). Surgically amenable painful spinal deformities such as sagittal plane abnormalities should be ruled out, as should spinal instability by assessing plain films with flexion–extension views (case examples 3, 4). Conventional magnetic resonance imaging (MRI) is usually the ideal study utilized to rule out disc extrusion or sequestration, spinal canal or neuroforaminal stenosis during preoperative screening. If spinal canal stenosis or cauda equina compression is present, decompressive laminectomy or laminoplasty is indicated, which could alleviate pain caused by a neural impingement. Percutaneous placement of an epidural stimulation electrode can also be more difficult and dangerous in patients with symptoms of spinal stenosis. In patients who clearly have neuropathic pain in combination with a structural lesion (e.g., spinal stenosis or deformity), the placement of a laminectomy

style electrode during the decompression and/or stabilization procedure should be considered.

Case Example 1

A 47-year-old man presented with severe left L4 radicular pain, numbness, and a history of previous microdiscectomy at L4/L5. MRI study (Figure 4A,B) demonstrated a huge free fragment disc herniation at L3/4 and severe bilateral L4 and L5 root compression with severe spinal stenosis. The patient underwent left posterior microsurgical L3-L4 hemilaminectomy and discectomy with removal of the massive free fragment (Figure 4C). His symptoms completely resolved after the surgery.

Case Example 2

A 49-year-old man presented with T9/10 radicular symptoms, progressive paraplegia, and spasticity. MRI demonstrated a large (approximately 2 × 3 cm) intradural extramedullary schwannoma at T9 with severe spinal cord compression (Figure 5A,B). The patient was taken to the operating room, where he underwent a T9, T10, and partial T11 laminectomy, and the tumor was removed. The intraoperative photograph demonstrates the tumor, which occupied the entire width of the canal being removed (Figure 5C). The patient was seen at our clinic 2 weeks after the surgery, and he reported that all of his previous symptoms were resolved.

Case Example 3

A 26-year-old man presented with a long and complex history of medical and surgical issues related to Klippel–Feil syndrome. Autofusion of all cervical interspaces, except C2/3 and C4/5, was detected on lateral radiographs (Figure 6A) and three-dimensional computed tomography (CT) reconstruction (Figure 6B). The patient has undergone previous multilevel laminectomies for spinal cord stimulator lead placement with resultant postsurgical kyphosis and chronic neck pain in addition to his original neuropathic symptoms. There has been a progressive loss of spinal cord stimulator efficacy as a result of lead migration in association with a worsening structural deformity. He had a 5-year history of neck pain radiating down both arms and into his thoracic spine. The patient described his pain as “deep” and “tense”

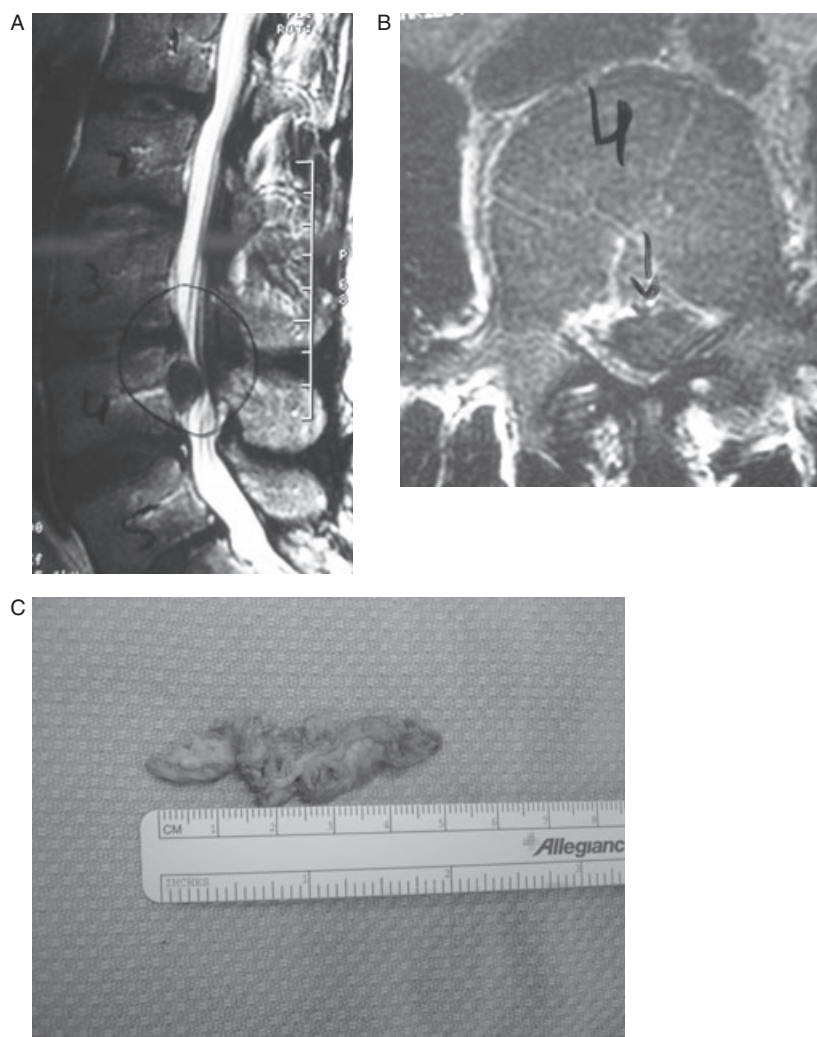


Figure 4 Sagittal (A) and axial (B) T2-weighted magnetic resonance images demonstrating free fragment disc herniation at L3/4. Intraoperative photograph of removed free fragment (C).

and noted nocturnal numbness and tingling of upper extremities. There was no evidence of cord compression on the CT myelograms, but plain films with flexion/extension views demonstrated instability at C4/5. The decision was made to proceed with anterior cervical discectomy, fusion, and plating at C4/5 and C2 to C5 posterior fusion, instrumentation, and revision of spinal cord stimulator. A significant decrease in the kyphotic angulation was achieved (Figure 6C), the patient reported that his previous discomfort in the neck and arms improved considerably, and he reported about 50% pain relief at 6-month follow-up.

Case Example 4

A 47-year-old man with a history of cervical instability underwent a C1-C3 fusion with sublaminar wires at another institution before he was seen at our clinic. The patient developed progressively

worsening neck pain and spastic quadriparesis in association with burning dysesthesias into both upper extremities. He had been set up to undergo placement of percutaneous spinal cord stimulator leads by another physician. The patient was seeking a second opinion at our clinic and was found to have a pseudoarthrosis with broken wires and gross spinal instability (Figure 7A,B) in association with multilevel spinal stenosis and cord compression (Figure 7C). After undergoing a multilevel anterior posterior decompression and fusion (Figure 7D,E), his neck pain and burning dysesthesias resolved with no change in spastic paraparesis.

Most clinicians find psychological or psychiatric assessment to be a valuable component for appropriate patient selection for SCS [10–13]. Patients with active psychosis, major personality disorders, serious cognitive deficits, secondary gain issues, or serious drug/alcohol addictions are

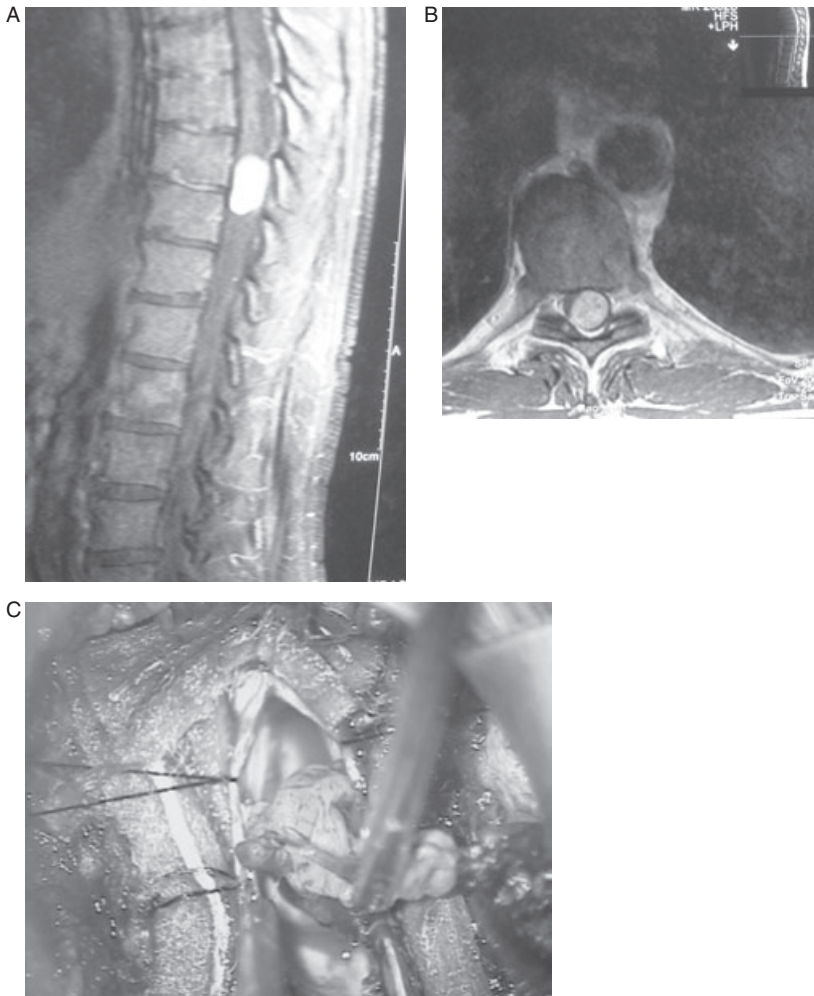


Figure 5 Magnetic resonance imaging T2-weighted image with sagittal (A) and axial (B) view demonstrating a large intradural, extramedullary schwannoma at T9. Schwannoma, intraoperative image (C).

routinely screened out for nonsurgical therapies. Significant psychological issues have a strong negative predictive value for outcome. Mild psychological disturbances such as reactive depression and somatization are common for this patient population and are not necessarily contraindications for implantation. However, the majority of psychological factors can be successfully managed with psychological intervention, thus allowing those patients to undergo SCS implantation.

Test Stimulation

The introduction of percutaneously placed epidural electrodes allows a therapeutic trial stimulation after longitudinal mapping of the epidural space for optimal electrode positioning [14]. It is frequently required by insurance companies that pain relief be demonstrated before a patient can be selected for permanent implantation of a stimula-

tor. Patients with a mixed pain syndrome in whom neuropathic symptoms coexist with nociceptive pain generators (e.g., tumor-related neural compression) may respond to either neurostimulation or intraspinal morphine administration. Therefore, performing temporary implantation in such cases is very important. Although test stimulation helps to exclude patients in whom the topographical appropriateness of stimulation cannot be accomplished for neuropathological or anatomical reasons [15], it cannot be considered to be a reliable predictor of success. In one study, only a 52–59% success rate was reported for the patients who underwent test stimulation before permanent device implantation [16,17]. In this study, multipolar systems have significantly improved clinical reliability over unipolar systems. The use of percutaneous versus plate electrodes could be partially responsible for such suboptimal outcomes [18,19].

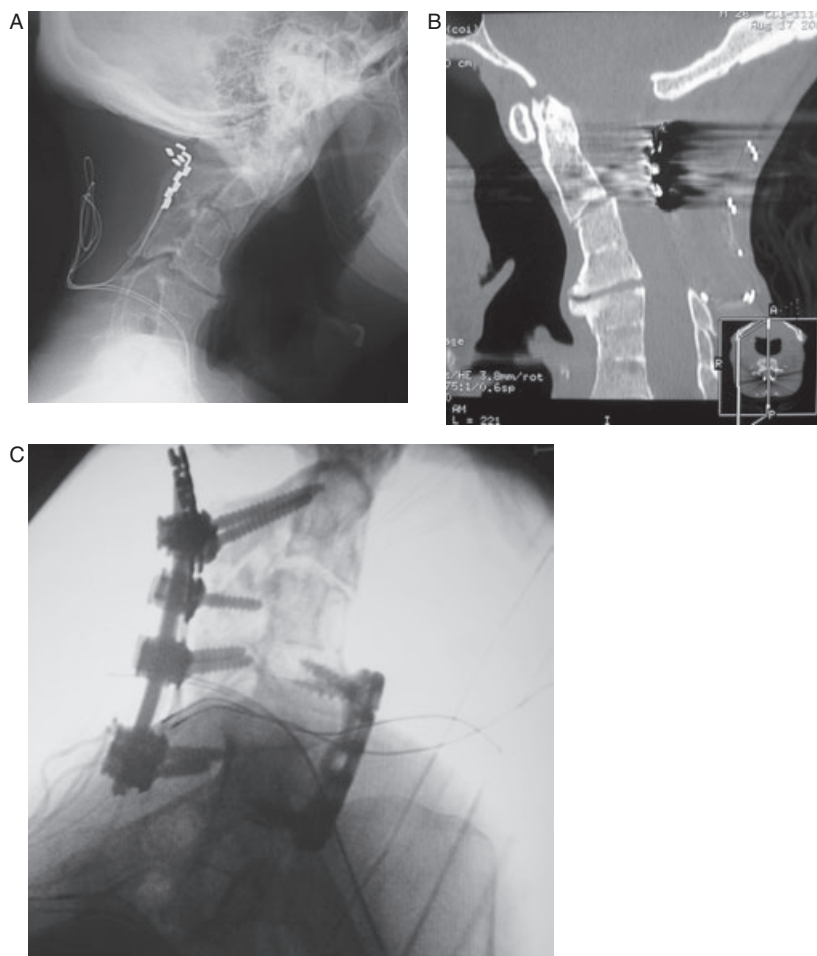


Figure 6 Lateral (A) cervical spine plain X-ray and sagittal three-dimensional computed tomography reconstruction (B) demonstrating multiple fused levels consistent with diagnosis of Klippel–Feil syndrome. Intraoperative fluoroscopic images (C) demonstrating a significant decrease in the kyphotic angulation after the surgery.

Tolerance of paresthesias, greater than 50% pain relief, and overall patient satisfaction should be demonstrated in order for test stimulation results to be considered positive. Other relative requirements include improved functional level, reduced usage of pain medications, and reduced reliance on the healthcare system [2]. If trial therapy provides sufficient relief from pain, the patient can be scheduled for another procedure and receive permanent implants. The authors' preferred method of trialing patients is to place a laminectomy-style lead in an awake patient under monitored anesthesia care (MAC) anesthesia with intraoperative mapping of the coverage. The patient is then sent home for a week or two with an external control device. This is followed by either removal of the leads (unsuccessful trial) or placement of an implantable pulse generator (IPG) that gets connected to the already implanted leads that have been secured to the dura and spinous processes in order to minimize the potential for lead migration. In the case of an

unsuccessful trial, other treatment options are explored.

Failed Back Surgery Syndrome

Inappropriate or inadequate surgery is the most common cause of FBSS [20]. Other conditions that can be responsible for FBSS include permanent neural injury, arachnoiditis, epidural fibrosis, radiculitis, microinstability of the lumbar structures, and recurrent disc herniation. Patients typically complain of greater radicular discomfort than axial back pain. Neurological evaluation may demonstrate deficits related to a history of prior surgery and should be correlated with the patient's current complaints. Although imaging studies are often obscured by metal hardware artifacts, they can be helpful in establishing a diagnosis. CT myelography with water-soluble contrast can sometimes be helpful in identifying problems amendable to reoperation (case example 5). If repeated surgery fails to adequately address a

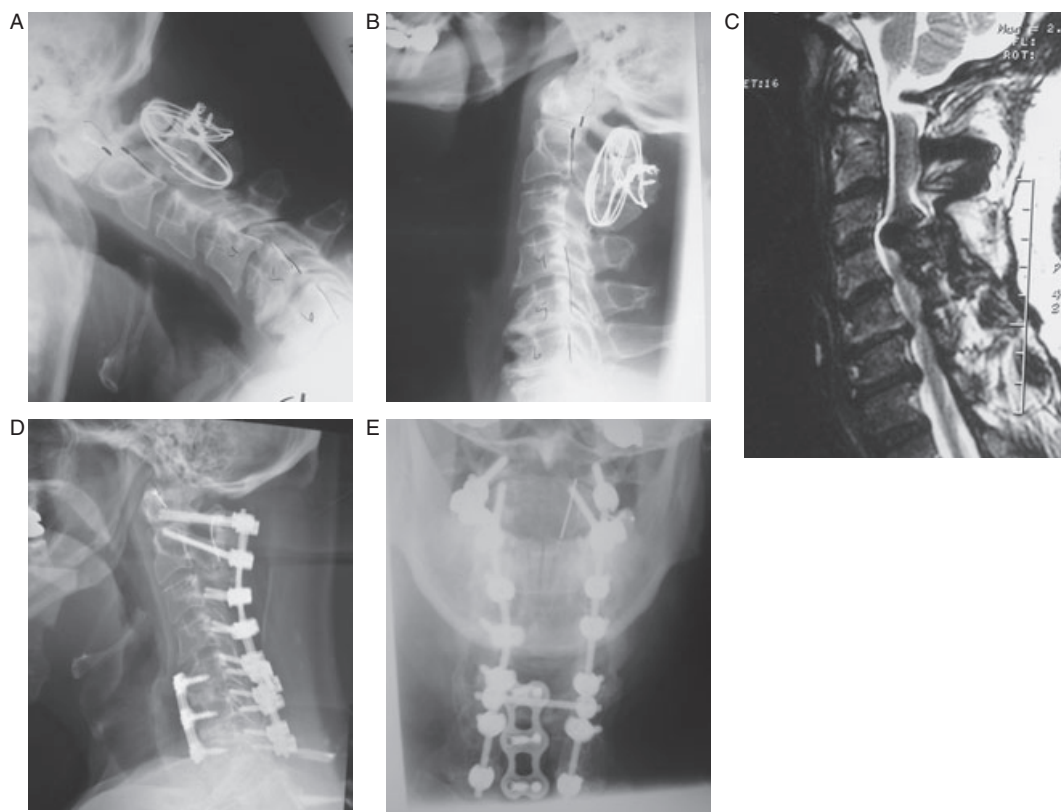


Figure 7 Lateral cervical spine plain X-ray flexion view (A) demonstrating approximately 3 mm of anterolisthesis of C1 on C2. Extended view in the same patient demonstrates 2 mm of retrolisthesis (B). Magnetic resonance imaging (C) demonstrating moderate central canal stenosis at C4/5 and critical central canal stenosis at C5/6 with associated inflammation and cord edema, and severe central canal stenosis at C6/7. Postoperative radiographs: lateral (D) and AP (E) views demonstrating posterior fusion construct with dual rods and transpedicular screws extending through C1 to C7.

patient's condition, SCS alone or in combination with reconstructive surgery should be considered (case examples 6 and 7). Contrast-enhanced MRI studies could help to distinguish between recurrent disc herniation and postoperative scarring. Radiographic studies (plain films with flexion/extension) are performed to rule out instability. Assessment of fusion is performed with CT using three-dimensional reconstruction. Provocative discography can be performed to determine whether anatomical abnormalities identified at certain levels on imaging studies are clinically significant and the individual patient's characteristic pain can be reproduced during the procedure. Unless there are clear indications, further surgeries should be performed after very careful considerations. North et al. [21,22] evaluated the efficacy of reoperation versus SCS for FBSS in a prospective, randomized study. The frequency of crossover to the alternative procedure was used as an outcome measure. They demonstrated that SCS was more successful than reoperation, as patients

initially randomized to SCS were significantly less likely to crossover, and patients randomized to reoperation required increased opiate analgesic use considerably more often than those randomized to SCS.

Case Example 5

An 81-year-old man with a long history of low back pain and lower extremity radicular symptoms, who previously underwent three surgeries on his lumbar spine, was diagnosed with FBSS. Imaging studies of the lumbosacral spine demonstrated severe multilevel degenerative changes with degenerative scoliosis. Lumbar spine myelography (Figure 8A,B) with CT myelogram (Figure 8C) identified a possible cause of patient's symptoms. Severe central neural canal stenosis was found at T12/L1 and moderate stenosis at L1/L2. The patient underwent T12 through S1 lumbar decompression, instrumentation, and fusion with bone morphogenetic protein. The patient has

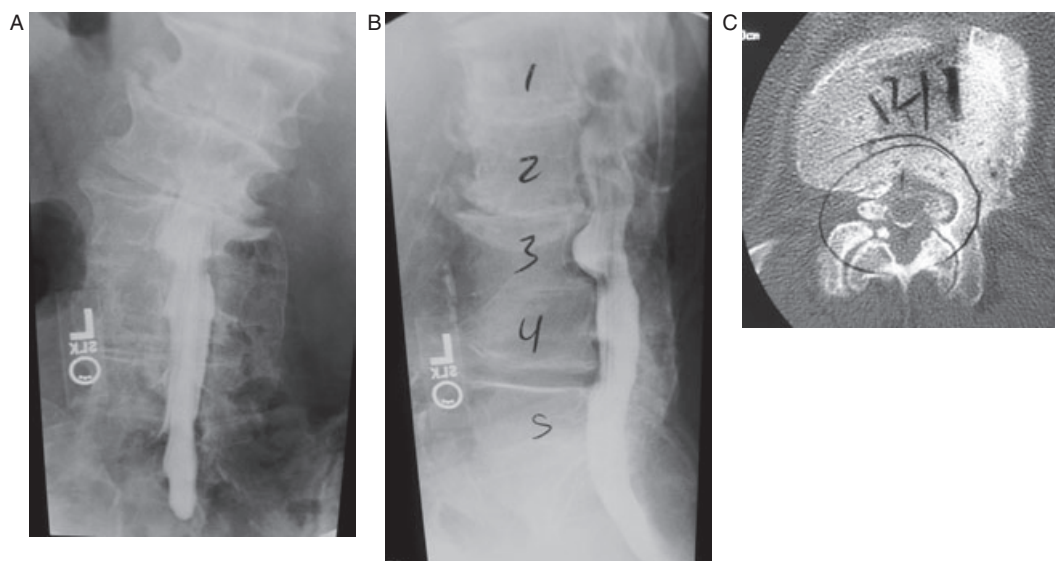


Figure 8 AP (A) and lateral (B) plain film myelography with confirmatory computed tomography myelography (C) demonstrating severe (T12/L1) and moderate (L1/L2) central neural canal stenosis.

been doing well at 1-year follow-up, and he has been able to significantly decrease his use of narcotic pain medication.

Case Example 6

A 56-year-old patient presented with a more than 15-year history of progressively worsening bilateral lower extremity and low back dysesthetic neuropathic pain. Five years ago, he underwent an L4-S1 decompression with posterior instrumentation and fusion procedure to alleviate his symptoms. Unfortunately, the patient reported no significant relief. Subsequent conservative therapies consisting of physical therapy, various epidural and nerve root injections, and medications provided no sustained benefit. He was diagnosed with FBSS, dorsal nerve root injury at L5, and since that time was gradually increasing his narcotic pain medications.

The patient was undergoing preoperative evaluation for a neurostimulation device implantation. He described his back pain as constant aching that is exacerbated with certain types of motion. Plain radiographs were performed with flexion-extension views, then a broken sacral screw and pseudoarthrosis at L5/S1 (Figure 9A,B) with a moderate level of instability were found. In addition, his bilateral lower extremity discomfort was very constant and described as “jabs of electrical pain and walking on bare bones” with radiation toward his ankles and calves. MRI studies demonstrated no central canal or nerve root impinge-

ment (Figure 9C). Neurological examination revealed weakness in his left foot and decreased sensation to pinprick below the knee bilaterally with bilateral patchy areas of hyperpathia in the L5 distribution.

The patient was felt to have neuropathic pain as a result of multilevel root stretch injuries and underwent a combined redo instrumentation and fusion with individually placed root stimulators (Figure 9D,E). At 6-month follow-up, the patient reported that the previous pain in his back and lower extremities decreased by 80%, and he was able to significantly decrease his pain medications.

Case Example 7

A 79-year-old woman underwent a series of back surgeries (laminectomy in 2001, fusion in 2002, and redo fusion in 2003) to treat her low back pain. She developed chronic debilitating low back pain and right lower extremity radicular symptoms and required complete assistance with her daily living. Physical therapy, functional rehabilitation, anti-inflammatory agents, and narcotic medications failed to provide relief. She was unable to stand for more than a minute and could not walk. Her pain became exacerbated with standing and any type of motion and was described as a burning and stabbing discomfort located in her lower back, groin, anterior thigh, and right leg. She had kyphotic spinal deformity with intense paraspinal muscle spasm. Neurological examination revealed three

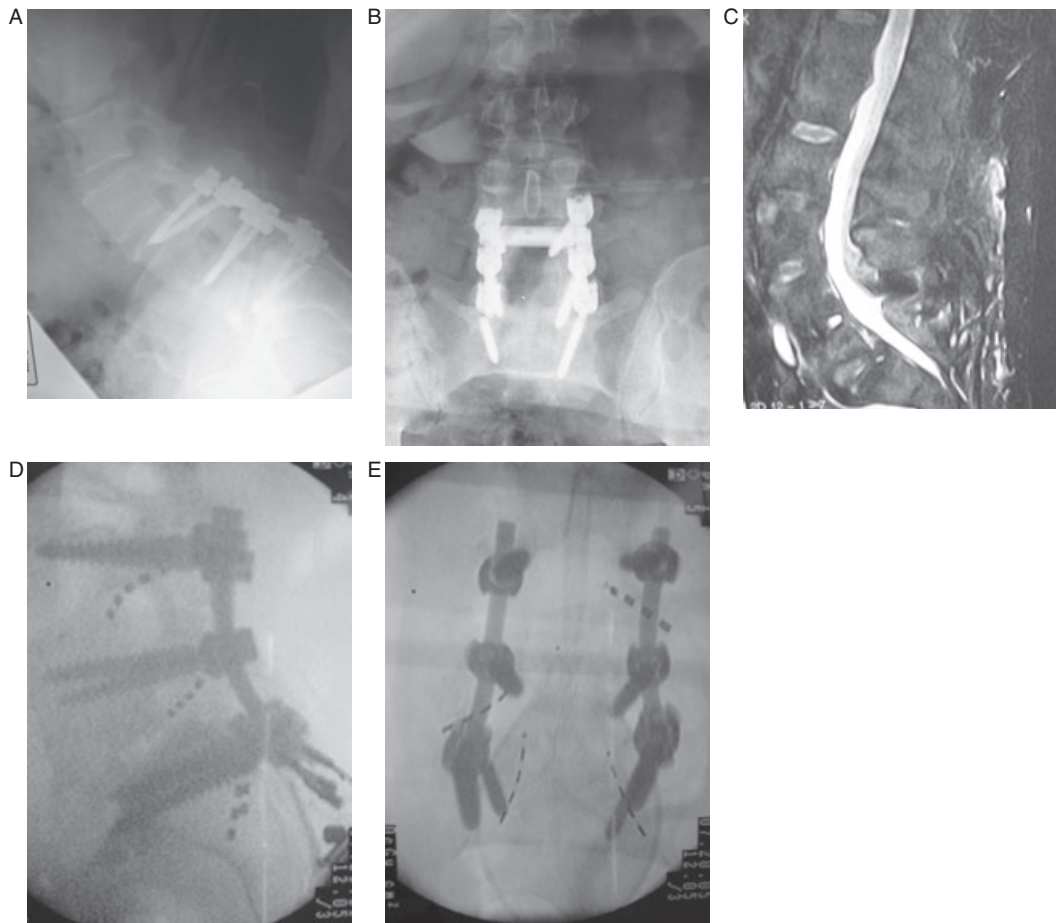


Figure 9 AP (A) and lateral (B) plain films demonstrating a previous L4-S1 instrumented fusion with pseudoarthrosis at L5/S1 and broken right S1 screw. Magnetic resonance imaging demonstrating no central canal or nerve root impingement (C). Intraoperative fluoroscopic images, lateral (D) and AP (E) with individually placed root stimulators.

out of five motor strength in the right iliopsoas and quadriceps, and hypersensitivity in the right L2 distribution with decrease reflexes.

A CT myelogram demonstrated extensive post-operative changes of L3/L5 laminectomy and posterior fusion with no signs of central or foraminal stenosis. Overall good positioning of the hardware was found with the exception of the right L2 pedicle screw, which appeared to be violating the pedicle and irritating the nerve root.

The patient subsequently underwent removal of the right L2 pedicle screw and a portion of the rod. She felt initial relief of her symptoms, improved overall mobility as well as the functional capacity in her leg, but unfortunately, her symptoms slowly began to return within 6 months.

Electromyography and nerve conduction studies demonstrated L4 radiculopathy. An L4 transforaminal epidural steroid injection was performed, which had no effect on her symptoms.

SCS therapy was then considered. Patient underwent extensive psychological evaluation, and although it revealed mild symptoms of depression, it was determined that she was an appropriate candidate for test stimulation implantation. SCS trial implantation (Figure 10) demonstrated good paresthesia coverage with about 50% pain reduction in her right lower extremity. It was decided to proceed with permanent device implantation. At 6-month follow-up, the patient reported that her discomfort in the right thigh and leg remained reduced by about 50%, and she was able to return to a more active life style.

Conclusions

Clinical and neurological evaluation, complete diagnostic workup, behavioral assessment, and a screening trial are all essential to determine a patient's suitability for SCS implantation. A cor-

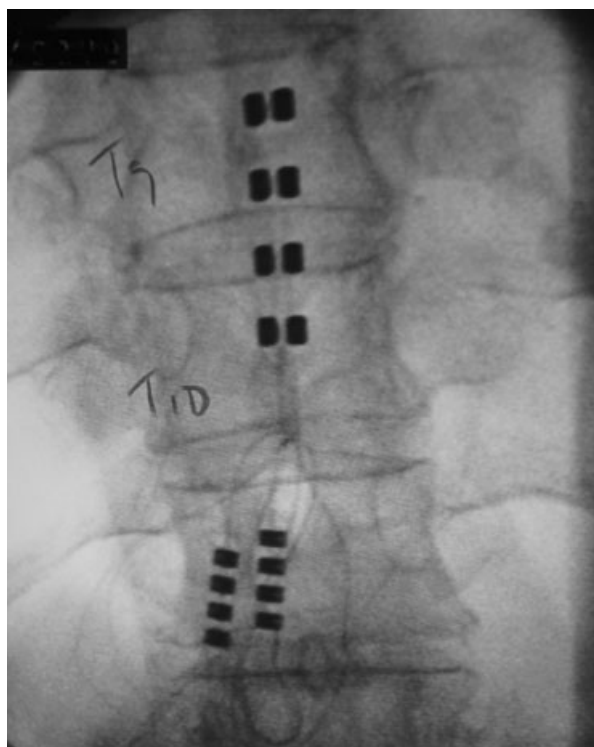


Figure 10 Intraoperative fluoroscopic image, trial spinal cord stimulation placement.

rect diagnosis and appropriate indications will help to achieve optimal treatment results and improve quality of life for a considerable number of patients suffering from intractable pain.

References

- 1 Cameron T. Safety and efficacy of spinal cord stimulation for the treatment of chronic pain: A 20-year literature review. *J Neurosurg* 2004;100(3 suppl Spine):254–67.
- 2 Windsor RE, Falco FJ, Pinzon EG. Spinal cord stimulation in chronic pain. In: Lennard TE, ed. *Pain Procedures in Clinical Practice*, 2nd edition. Philadelphia, PA: Hanley & Belfus; 2000:377–94.
- 3 Krames E. Implantable devices for pain control: Spinal cord stimulation and intrathecal therapies. *Best Pract Res Clin Anaesthesiol* 2002;16(4):619–49.
- 4 Simpson BA. Spinal cord stimulation in 60 cases of intractable pain. *J Neurol Neurosurg Psychiatry* 1991;54(3):196–9.
- 5 Alo KM, Holsheimer J. New trends in neuromodulation for the management of neuropathic pain. *Neurosurgery* 2002;50(4):690–703; discussion 703–4.
- 6 Lang P. The treatment of chronic pain by epidural spinal cord stimulation—A 15 year follow up; present status. *Axone* 1997;18(4):71–3.
- 7 Meyerson BA, Linderoth B. Spinal cord stimulation. In: Loeser JD, ed. *Bonica's Management of Pain*. Philadelphia, PA: Lippincott Williams & Wilkins; 2001:1856–76.
- 8 Backonja MM. Painful neuropathies. In: Loeser JD, ed. *Bonica's Management of Pain*, 3rd edition. Philadelphia, PA: Lippincott Williams & Wilkins; 2001:371–88.
- 9 Galer BS, Jensen MP. Development and preliminary validation of a pain measure specific to neuropathic pain: The Neuropathic Pain Scale. *Neurology* 1997;48(2):332–8.
- 10 Block AR, Ohnmeiss DD, Guyer RD, Rashbaum RF, Hochschuler SH. The use of presurgical psychological screening to predict the outcome of spine surgery. *Spine J* 2001;1(4):274–82.
- 11 Burchiel KJ, Anderson VC, Wilson BJ, et al. Prognostic factors of spinal cord stimulation for chronic back and leg pain. *Neurosurgery* 1995;36(6):1101–10; discussion 1110–1.
- 12 Kupers RC, Van den Oever R, Van Houdenhove B, et al. Spinal cord stimulation in Belgium: A nationwide survey on the incidence, indications and therapeutic efficacy by the health insurer. *Pain* 1994;56(2):211–6.
- 13 North RB, Kidd DH, Wimberly RL, Edwin D. Prognostic value of psychological testing in patients undergoing spinal cord stimulation: A prospective study. *Neurosurgery* 1996;39(2):301–10; discussion 310–1.
- 14 North R. Spinal cord stimulation for the failed back surgery syndrome. In: Gildenberg PL, Tasker R, eds. *Textbook of Stereotactic and Functional Neurosurgery*. New York: McGraw-Hill; 1998:1611–20.
- 15 Simpson BA. Selection of patients and assessment of outcome. In: Simpson BA, ed. *Electrical Stimulation and the Relief of Pain*, Vol. 15. Elsevier: Pain Research and Clinical Management; 2003:237–49.
- 16 North RB, Kidd DH, Zahurak M, James CS, Long DM. Spinal cord stimulation for chronic, intractable pain: Experience over two decades. *Neurosurgery* 1993;32(3):384–94; discussion 394–5.
- 17 Kumar K, Toth C, Nath RK, Laing P. Epidural spinal cord stimulation for treatment of chronic pain—Some predictors of success. A 15-year experience. *Surg Neurol* 1998;50(2):110–20; discussion 120–1.
- 18 Villavicencio AT, Leveque JC, Rubin L, Bulsara K, Gorecki JP. Laminectomy versus percutaneous electrode placement for spinal cord stimulation. *Neurosurgery* 2000;46(2):399–405; discussion 405–6.
- 19 North RB, Kidd DH, Petrucci L, Dorsi MJ. Spinal cord stimulation electrode design: A prospective, randomized, controlled trial comparing percutaneous with laminectomy electrodes: Part II—Clinical outcome. *Neurosurgery* 2005;57(5):990–6.

- 20 North RB, Campbell JN, James CS, et al. Failed back surgery syndrome: 5-year follow-up in 102 patients undergoing repeated operation. *Neurosurgery* 1991;28(5):685-90; discussion 690-1.
- 21 North RB, Kidd DH, Farrokhi F, Piantadosi SA. Spinal cord stimulation versus repeated lumbosacral spine surgery for chronic pain: A randomized, controlled trial. *Neurosurgery* 2005;56(1):98-106; discussion 106-7.
- 22 North RB, Kidd DH, Piantadosi S. Spinal cord stimulation versus reoperation for failed back surgery syndrome: A prospective, randomized study design. *Acta Neurochir Suppl* 1995;64:106-8.