

Intraoperative three-dimensional fluoroscopy-based computerized tomography guidance for percutaneous kyphoplasty

ALAN T. VILLAVICENCIO, M.D., SIGITA BURNEIKIENE, M.D., KETAN R. BULSARA, M.D.,
AND JEFFREY J. THRAMANN, M.D.

*Boulder Neurosurgical Associates, Boulder Community Hospital, Boulder, Colorado;
and University of Missouri, Columbia, Missouri*

Object. Percutaneous kyphoplasty is an established method for the treatment of pathological vertebral compression fractures (VCFs). This procedure is usually performed with the aid of biplanar fluoroscopic image guidance. There are currently no published clinical studies in which the use of three-dimensional (3D) image guidance to facilitate this technique has been evaluated. The purpose of this study was to evaluate the efficacy of isocentric fluoroscopy-based navigation for the kyphoplasty procedure, with special reference to operating time and the amount of radiation exposure.

Methods. A prospective clinical study was performed in which 11 consecutive patients with painful pathological VCFs that did not respond to conservative treatment underwent the kyphoplasty procedure. During this procedure, cannulation of the pedicle and vertebral body was performed with the aid of isocentric 3D fluoroscopy visualization. Total operating time and intraoperative fluoroscopy time for this group was compared with a cohort of nine patients who underwent the procedure prior to the availability of isocentric fluoroscopy (only biplanar fluoroscopy was used). Possible complications such as cement extravasations were evaluated during the procedure and on postoperative computerized tomography scans.

The mean duration of surgery for the 3D isocentric fluoroscopic guidance group was 60 minutes (range 36–89 minutes) for one-level and 68.5 minutes (range 65–75 minutes) for two-level cases. Because of a learning curve with the equipment, the operating time for the initial cases was significantly longer than with the later ones. Even with the initial cases included, the mean operating time was shorter compared with the biplanar fluoroscopy-assisted procedures, which averaged 69.2 minutes (range 44–113 minutes) for one-level procedures. This difference was not statistically significant. The mean fluoroscopy exposure time was 41.3 seconds (range 25–62 seconds) in the isocentric fluoroscopy-assisted procedures, with an additional 40 seconds of fluoroscopy time used for the 3D fluoroscopy “spin,” compared with 293.2 seconds (range 180–400 seconds) in the biplanar fluoroscopy-assisted procedures. The difference was statistically significant ($p = 0.02$). All pedicles were accessed without difficulty and no complications were encountered in either group of patients.

Conclusions. The main advantage of isocentric fluoroscopy is the significant reduction in radiation exposure for the patient and surgical staff without an increase in the mean operating time. This technique is a significant advancement over biplanar fluoroscopy in this setting.

KEY WORDS • image guidance • kyphoplasty • spine surgery •
three-dimensional fluoroscopy

An estimated 700,000 VCFs occur every year in the US.³ Osteoporotic fractures of the spine are a common cause of morbidity,¹² and lead to a 23% increase in mortality rates¹⁶ in elderly patients. Not all fractures can be treated conservatively.

The kyphoplasty and vertebroplasty procedures have

Abbreviations used in this paper: AP = anteroposterior; CT = computerized tomography; MR = magnetic resonance; OR = operating room; PMMA = polymethyl methacrylate; VB = vertebral body; VCF = vertebral compression fracture; 3D = three-dimensional.

recently been developed for their potential to provide immediate pain relief and stability with minimally invasive surgical intervention. A 95 to 100%^{10,24} success rate in terms of pain relief after kyphoplasty has been reported, in comparison with 42% in a conservatively treated patient group.²⁶

Since being introduced into surgical practice in the late 1990s, kyphoplasty has become the preferred method for treating osteoporotic VCFs for many spine surgeons,^{7,10,18} compared with the vertebroplasty procedure for most interventional radiologists. The potential advantages of kyphoplasty over vertebroplasty include the avoidance of

high-pressure injections, uncontrolled fills, and the ability to restore vertebral height or reduce the associated spinal deformity.^{4,7,11,13,18,22,24,25} Other potential surgical risks, such as cement leaks, have also reportedly been reduced in comparison with vertebroplasty.^{11,13}

Complication rates reported in the literature on kyphoplasty vary from 0 to 9.8%.^{4,6,11,21,24} These events are commonly related to the initial cannulation of the pedicle and VB and include spinal cord injury, pulmonary cement embolus, epidural hematoma, epidural cement extravasation, cerebrospinal fluid leakage, and transient adult respiratory distress syndrome. Lieberman, et al.,¹⁹ reported a 20% balloon rupture rate and an 8.6% cement extravasation rate.

Significantly more advanced intraoperative image guidance techniques have recently become more widespread and available, but have not been reported in association with the kyphoplasty procedure. We describe the first series of patients who underwent this minimally invasive procedure with the aid of isocentric fluoroscopy-based image guidance in an effort to decrease the risk of complications, the operating time, and the amount of radiation exposure for both the patient and the OR personnel.

CLINICAL MATERIAL AND METHODS

Patient Population

This is a prospective study in which we evaluated all patients treated consecutively between November 2003 and March 2004 in whom the kyphoplasty procedure was performed with the assistance of isocentric fluoroscopic imaging guidance. Operating and biplanar fluoroscopy time in this group was compared with these two factors a historical cohort of patients in whom only biplanar fluoroscopy had been used. Possible complications such as extravasations were evaluated during the procedure and on postoperative CT scans.

Eleven patients (six men and five women) were included in the isocentric fluoroscopy–assisted group. The mean age of the patients was 78.1 years (range 39–99 years). Eight patients (72.7%) had a one-level fracture, whereas three (27.3%) had vertebral fractures at two levels. Ten patients (90.9%) had primary osteoporotic VCFs and one (9.1%) was treated for osteolytic metastatic disease. Three lumbar (L1–5) and 11 thoracic (T4–12) kyphoplasty procedures were performed.

The historical cohort of nine consecutive patients in whom only biplanar fluoroscopy was used during the kyphoplasty procedure was reviewed retrospectively. This group consisted of three men and six women; the mean age of these patients was 75.2 years (range 63–92 years). Single-level kyphoplasty procedures were performed in eight patients (88.9%), and one (11.1%) had fractures at two levels. All nine patients were treated for primary osteoporotic VCFs. Seven lumbar (L1–4) and three thoracic (T6–12) procedures were performed.

The demographic data in these patients show that both groups were homogeneous. All patients in both groups presented with painful pathological VCFs that did not respond to conservative treatment, which included observation, physiotherapy, and bracing. Before the surgery, conventional AP and lateral radiographs and MR imaging studies were obtained to confirm the diagnosis of VCF

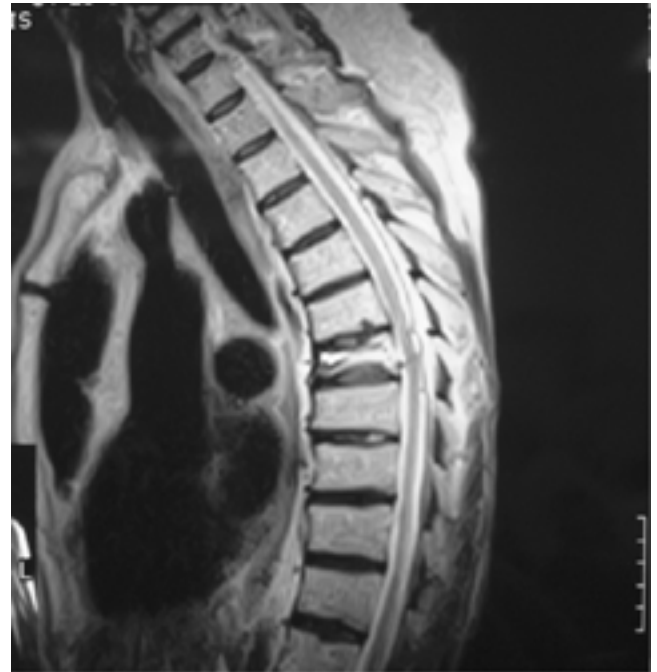


Fig. 1. Admission MR image demonstrating a T-7 VCF.

(Fig. 1). We used T₂-weighted and short-tau inversion–recovery sequence MR imaging to identify bone marrow edema, which was thought to indicate a recent fracture. Kyphotic deformity was often associated with the fracture. All patients presented clinically with focal back pain that was exacerbated by standing or walking and relieved by bed rest. Other possible causes of back pain were evaluated and excluded.

Surgical Procedure

Percutaneous kyphoplasty with 3D isocentric fluoroscopic guidance was performed after induction of general endotracheal anesthesia in eight of 11 cases, and after light inhalational and neuroleptic anesthesia was induced without intubation in the other three patients. The patients were placed prone on a radiolucent Jackson table. After AP and lateral fluoroscopic localization of the lesion, a small midline incision was made over the spinous process one or two levels rostral to this area. This incision was continued through the subcutaneous tissues and dorsal fascia with monopolar electrocautery and in a subperiosteal fashion along the spinous process bilaterally. The Stealth computer volumetric neuronavigational frame was then attached to the spinous process. Multiple axial-plane tomographic images were then obtained during a “spin” by using a 3D isocentric fluoroscopic unit (Siremobil Iso-C 3D; Siemens Medical Solutions, Erlangen, Germany). Each “spin” required 2 minutes in which to acquire and reconstruct 100 images. There was no surgeon-dependent registration step; the registration process is automated.

Images were transferred to a Stealth Station Treon Treatment Guidance System (Medtronic, Louisville, CO) and reconstructed into 3D volumes consisting of 256 isotropic pixels (Fig. 2). An integrated navigation interface

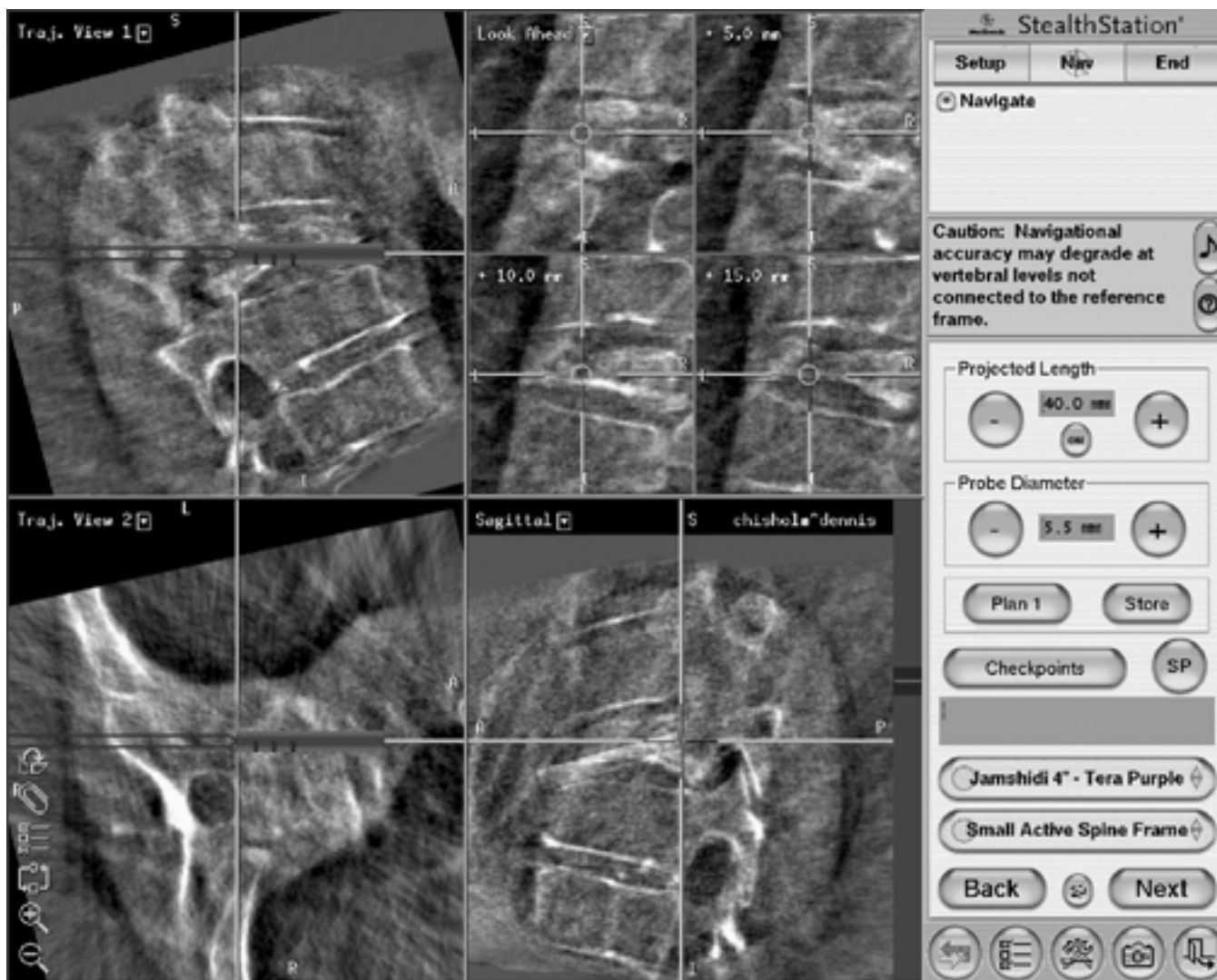


Fig. 2. Monitor displays depicting intraoperative isocentric fluoroscopic guidance with the Stealth Treon computer volumetric navigation system.

(NaviLink) was used for direct connection to navigation systems for 3D reconstruction.

All procedures were performed via a transpedicular approach by using an 11-gauge Jamshidi needle inserted percutaneously at the lateral border of the pedicle or at the junction of the transverse process and facet joint. The transpedicular approach into the posterior portion of the VB was performed with the aid of real-time isocentric fluoroscopic guidance (Fig. 2). This effectively eliminated the need for biplanar fluoroscopy during the cannulation step of the procedure in all 11 cases.

After transpedicular cannulation of the VB by using the Jamshidi needle, a K-wire was placed, followed by the kyphoplasty cannula. An inflatable bone tamp (KypHx; Kyphon, Sunnyvale, CA) was then introduced through the cannula. The balloon was gradually inflated under monometric control until vertebral height was restored and the collapsed endplates were elevated as much as possible; during these maneuvers contact of the balloon with ver-

tebral cortical margins was usually evident. The balloon inflation volume did not exceed 250 psi in any case. Maximum pressures were reached in gradual 50-psi increments. Inflatable bone tamps were used bilaterally to achieve uniform restoration of the compression. After maximum pressures were obtained, PMMA, a radiopaque bone cement (Surgical Simplex P; Howmedica, Rutherford, NJ), was prepared and slowly injected into the VB. In the formulation we used, 1.5 g of Zinacef (cefuroxime sodium) and 6 g barium sulfate (Bryan, Woburn, MA) were included in the PMMA. The void created by the inflatable bone tamp was gradually filled while maintaining biplanar fluoroscopic visualization. Filling of interstices of fractured bone was observed with the aid of fluoroscopy (Fig. 3). Continuous visual control helped to obtain adequate filling and avoid leakage. In no case was cement extravasation outside the VB noted.

In the nine cases that were analyzed retrospectively and for which isocentric fluoroscopy guidance was not used,

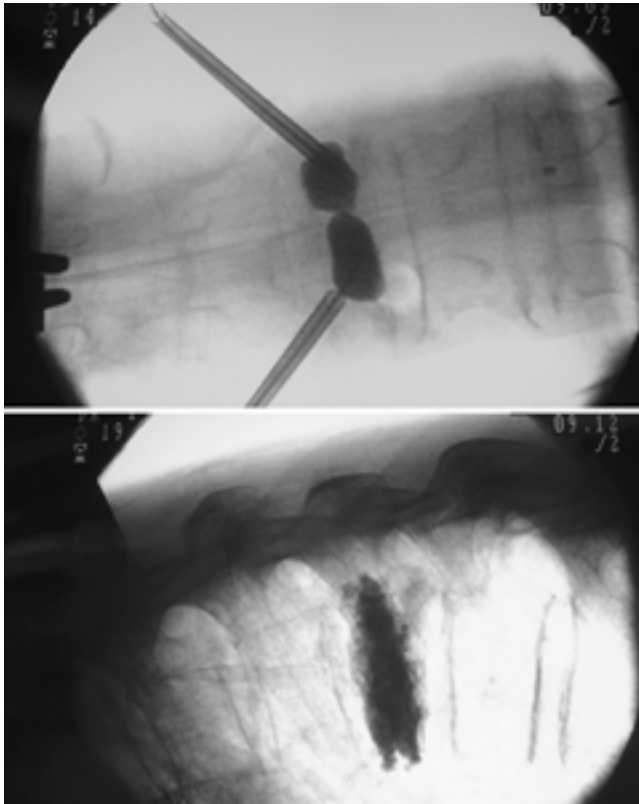


Fig. 3. Intraoperative fluoroscopy images of percutaneous balloon kyphoplasty. *Upper:* Transpedicular approach, AP view of thoracic spine at the T-7 level with inflatable bone tamp inserted within the cavity. *Lower:* After balloon kyphoplasty the presence of PMMA is observed at the T-7 thoracic VB.

standard biplanar fluoroscopy was used for cannulation of the pedicles and VBs. A detailed description of this procedure has been published elsewhere.²

RESULTS

The mean operating time for isocentric fluoroscopy–assisted cases was 60 minutes (range 36–89 minutes) for one-level procedures and 68.5 minutes (range 65–75 minutes) for two-level procedures (Table 1). Operating time for the initial cases (60–89 minutes) was significant-

TABLE 1

*Operating and radiation time with biplanar compared with isocentric fluoroscopy in patients undergoing kyphoplasty**

Procedure	OR Time (mins)	Radiation Time (secs)
isocentric fluoroscopy–assisted kyphoplasty		
one-level	60.0 (36–89)	41.3 (25–62)
two-level	68.5 (65–75)	41.3 (25–62)
biplanar fluoroscopy–assisted kyphoplasty		
one-level	69.2 (44–113)	293.2 (180–400)

* Values are given as the mean, with the range in parentheses.

ly longer than in the later cases (36–68 minutes). Nevertheless, the mean operating time was shorter compared with that in the biplanar fluoroscopy–assisted cases, which averaged 69.2 minutes (range 44–113 minutes) for one-level procedures. This difference was not statistically significant.

Minimal biplanar fluoroscopy time was used in the patient group with isocentric fluoroscopy–assisted surgery; this averaged 41.3 seconds (range 25–62 seconds) for both single- and multiple-level cases. An additional 40 seconds of fluoroscopy time was used for 3D fluoroscopy “spin.” In the nine retrospectively analyzed cases, in which surgery was performed without the assistance of isocentric fluoroscopy, the mean biplanar fluoroscopy time was 293.2 seconds (range 180–400 seconds). This difference was statistically significant ($p = 0.02$).

The mean blood loss was 9.6 ml (range 5–25 ml) for all cases, with no significant difference related to how many levels were treated or the imaging modality used. The procedure was well tolerated and successful. All pedicles were accessed without difficulty and no complications were encountered in either group of patients.

DISCUSSION

Initial transpedicular cannulation of the VB during both the vertebroplasty and kyphoplasty procedures is usually performed using biplanar fluoroscopy. In standard biplanar fluoroscopy, the needle is tapped down the pedicle with a mallet to a point just beyond the posterior cortex of the VB. This is confirmed with frequent fluoroscopy “snapshot” imaging to verify that the needle does not penetrate the medial wall of the pedicle.²² Although this method is usually adequate, it can be very cumbersome and time-consuming. In addition, sometimes the pedicle cannot be cannulated with the aid of plane fluoroscopy, thus resulting either in failure to insert the introducing trocar successfully into the VB, or reliance on a potentially more dangerous extrapedicular approach.

Garfin, et al.,¹¹ reported that complications related to the kyphoplasty procedure are mostly related to the needle insertion. They reviewed the literature and reported on two patients, one with partial motor loss in the lower extremities caused by improper placement of the insertion tools and cement injection into the spinal canal. The other case was complicated by an anterior spinal cord syndrome that was caused by a vertebral fracture through the pedicle–body junction when an extrapedicular approach was used. Barr, et al.,¹ reported transient radicular neuritis after vertebroplasty performed via a transpedicular approach. In another paper, investigators described a 1.3% rate of fracture involving the pedicle used for needle access for vertebroplasty in the mid- and upper thoracic spine.¹⁷ Another risk associated with this technique is the creation of dural tears.¹⁴ This problem is usually related to suboptimal visualization of the pedicular margins when using plain fluoroscopy in patients with osteoporosis.

It has been suggested that CT-guided transpedicular needle insertion and cement injection is safer than standard biplanar fluoroscopy.^{1,5,8,9} Barr, et al.,¹ described using sequential CT-based images to direct the needle. These authors concluded that use of CT guidance to monitor the

precise deposition of the cement represents a significant advantage when treating lesions in which severe osteolysis could allow canal or foraminal compromise. Barr and associates go on to conclude that even very severe osteolysis is not a contraindication to vertebroplasty when combined CT and fluoroscopy guidance are used. Gangi, et al.,⁸ stated that CT guidance increases precision, improves the results, and reduces complications. Nevertheless, use of standard CT scanning is expensive, time-consuming, and potentially results in increased amounts of radiation exposure for the patient and surgical staff. The combination of standard CT and fluoroscopy guidance is generally reserved for complex and high-risk procedures. Cyteval, et al.,⁵ recommended CT guidance “to facilitate accurate needle placement, particularly in the thoracic spine using transpedicular approach” and admits that “the disadvantage of CT guidance alone is the lack of real-time visualization of cement leaks.” Use of isocentric fluoroscopy combines the advantages of CT guidance and real-time fluoroscopic evaluation of the cement fill without increased cost or radiation exposure.

Because kyphoplasty candidates tend to be elderly patients with many potential comorbidities, it is essential to limit the complications in this patient population. Initial cannulation of the VB by using isocentric fluoroscopy potentially decreases the incidence of approach-related problems such as inadvertent medial or lateral wall penetration of the pedicle or VB. In difficult cases presenting with a near complete VB collapse or very small pedicles, this could be an especially useful addition. Fluoroscopic visualization may assist with precise anterior needle placement in cases in which the posterior cortex is disrupted.

Elimination of the need for biplanar fluoroscopy during this step also gives the surgeon room to stand in a much more desirable position without the need to reach around or under the fluoroscopy units. Although this technique does not completely eliminate the subsequent need for fluoroscopic images during the balloon tamp or bone filling phases, its overall effect in this series was to decrease the amount of radiation exposure for both the patient and the OR personnel while providing improved image guidance. For each case in this series, 41 seconds (range 25–62 seconds) of biplanar fluoroscopy time was used, in addition to 40 seconds of fluoroscopy time during isocentric “spin,” compared with 293 seconds (range 180–400 seconds) for the retrospectively studied cases in which isocentric image guidance was not used. This initial “spin” adds 2 minutes to the total operating time, and uses 40 seconds of biplanar fluoroscopy time, but the dose associated with it is equivalent to only 30 seconds of standard two-dimensional fluoroscopy. The surgical team does not even have to be in the same room as the patient during the acquisition phase of the image guidance process.

In this series, initial placement of the Jamshidi needle and K-wire was performed with the aid of 3D fluoroscopic visualization and reconstruction guidance. In contrast to standard two-dimensional fluoroscopy, this allowed for improved visualization of the unexposed spinal anatomy during surgery. When performing this surgical procedure with the aid of conventional biplanar fluoroscopic visualization, repeated repositioning is commonly required. This can be very time-consuming and troublesome, and

results in much more radiation exposure to the patient, surgeon, and all OR personnel. In this study, isocentric fluoroscopy use required one spin at the beginning of the operation. Whereas registration is based on anatomical landmarks in most types of navigational devices now in use, no manual registration is involved in isocentric fluoroscopy navigation. This eliminates a very time-consuming portion of other types of image guidance and also facilitates the achievement of the required degree of accuracy. Another potential advantage of intraoperative isocentric fluoroscopic navigation is that use of postoperative CT scans to evaluate placement of the cement can be eliminated. If there is any question, control isocentric spins can be obtained in the OR using isocentric fluoroscopy immediately postsurgery to document the results.

The image quality of 3D isocentric CT studies has previously been evaluated.²⁰ It was determined that high-contrast resolution was comparable to helical CT scans (0.9 line pairs/mm), and with a 60 to 80% lower radiation dose. This modality was also found to be sufficient for intraoperative control studies in the lumbar and thoracic spine.²³ A 100% rate of accuracy between intraoperative isocentric fluoroscopy and thin-slice postoperative CT scans has been demonstrated in studies assessing the accuracy of screw placement.¹⁵

In our study, the mean operating time was 60 minutes (range 36–89 minutes) for one-level and 68.5 minutes (range 65 to 75 minutes) for two-level procedures. A significant learning curve was observed; operating time for the initial few cases was significantly longer than in the later cases (Fig. 4). Compared with previously published data,²⁴ in which operating times with biplanar fluoroscopy averaged 30 to 45 minutes per spinal level, our results demonstrated increased operating time. Nevertheless, there were no ranges reported in the earlier studies and these numbers appear to have been based on the median operating time; the authors only stated that “performance time for kyphoplasty was typically 30–45 min per spinal level.” In our experience, the mean operating time was 69.25 minutes (range 44–113 minutes) for one-level procedures when only biplanar C-arm fluoroscopy was used.

System limitations for isocentric fluoroscopy could potentially be encountered when more than one level of fractured vertebrae is treated and these are separated by two or three levels. Image acquisition volume is approximately four or five spinal segments; therefore, a second spin might be required, adding to the surgery time and radiation dose. On the other hand, multiple fractures at adjacent levels could all potentially be approached using a single “spin,” and could further decrease the amount of radiation required.

CONCLUSIONS

The safety and accuracy of the minimally invasive percutaneous kyphoplasty procedure could be increased by using 3D fluoroscopic visualization for image guidance. Due to the small number of patients and the absence of complications, definitive evaluation of this procedure was outside the scope of this study and requires further investigation. Nevertheless, our study demonstrates that use

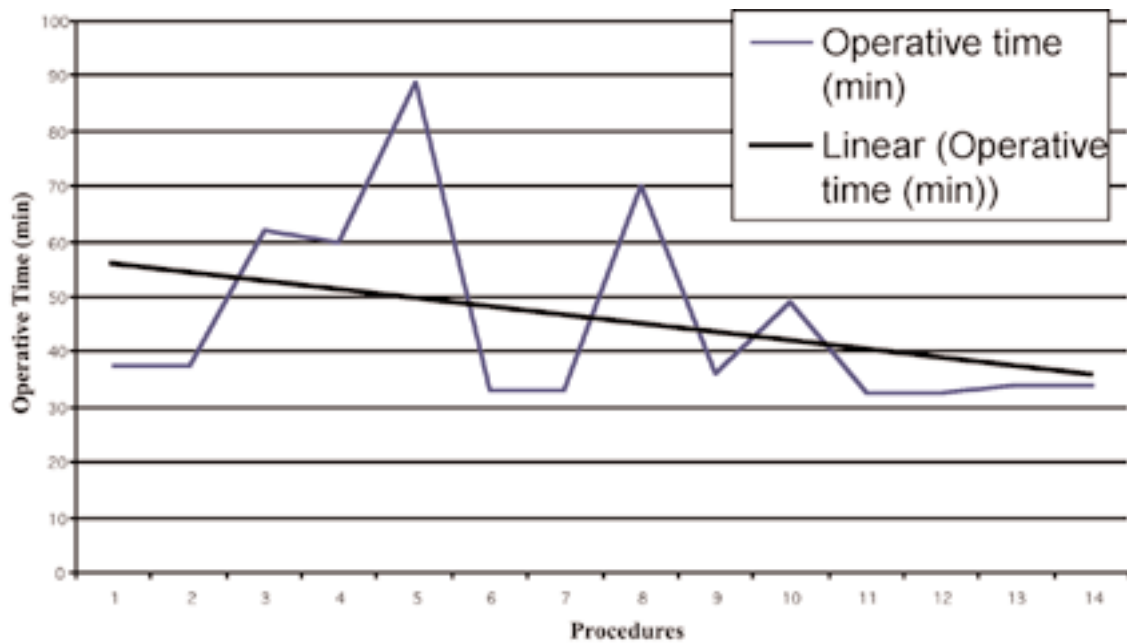


Fig. 4. Graph illustrating operating time as a function of the number of cases treated using 3D fluoroscopy-based CT guidance for percutaneous kyphoplasty. Note that total operating time is expressed per spinal level for the procedures 1, 2, 6, 7, 11, and 12 because they represent two-level kyphoplasty procedures.

of 3D isocentric fluoroscopy definitely does not increase the mean operating time. In our experience, the time was slightly decreased even with the learning curve, compared with the historical cohort of consecutive kyphoplasty procedures in which just biplanar C-arm fluoroscopy was used. The one advantage of isocentric 3D image guidance clearly demonstrated by this study was minimization of the radiation exposure to the patient and OR personnel.

References

- Barr JD, Barr MS, Lemley TJ, et al: Percutaneous vertebroplasty for pain relief and spinal stabilization. *Spine* **25**:923–928, 2000
- Carrino JA, Chan R, Vaccaro AR: Vertebral augmentation: vertebroplasty and kyphoplasty. *Semin Roentgenol* **39**:68–84, 2004
- Cooper C, Atkinson EJ, Jacobsen SJ, et al: Population-based study of survival after osteoporotic fractures. *Am J Epidemiol* **137**:1001–1005, 1993
- Coumans JV, Reinhardt MK, Lieberman IH: Kyphoplasty for vertebral compression fractures: 1-year clinical outcomes from a prospective study. *J Neurosurg Spine* **99**:44–50, 2003
- Cyteval C, Sarrabere MP, Roux JO, et al: Acute osteoporotic vertebral collapse: open study on percutaneous injection of acrylic surgical cement in 20 patients. *AJR* **173**:1685–1690, 1999
- Dudeney S, Lieberman IH, Reinhardt MK, et al: Kyphoplasty in the treatment of osteolytic vertebral compression fractures as a result of multiple myeloma. *J Clin Oncol* **20**:2382–2387, 2002
- Fourney DR, Schomer DF, Nader R, et al: Percutaneous vertebroplasty and kyphoplasty for painful vertebral body fractures in cancer patients. *J Neurosurg Spine* **98**:21–30, 2003
- Gangi A, Dietemann JL, Mortazavi R, et al: CT-guided interventional procedures for pain management in the lumbosacral spine. *Radiographics* **18**:621–633, 1998
- Gangi A, Kastler BA, Dietemann JL: Percutaneous vertebroplasty guided by a combination of CT and fluoroscopy. *AJNR* **15**:83–86, 1994
- Garfin SR, Reiley MA: Minimally invasive treatment of osteoporotic vertebral body compression fractures. *Spine J* **2**:76–80, 2002
- Garfin SR, Yuan HA, Reiley MA: New technologies in spine: kyphoplasty and vertebroplasty for the treatment of painful osteoporotic compression fractures. *Spine* **26**:1511–1515, 2001
- Goh LH, Tan SB, Liaw JS: Advances in surgical treatment of osteoporotic fractures of the spine. *Ann Acad Med Singapore* **31**:623–630, 2002
- Heini PF, Orlor R: Kyphoplasty for treatment of osteoporotic vertebral fractures. *Eur Spine J* **13**:184–192, 2004
- Hide IG, Gangi A: Percutaneous vertebroplasty: history, technique and current perspectives. *Clin Radiol* **59**:461–467, 2004
- Hott JS, Deshmukh VR, Klopfenstein JD, et al: Intraoperative Iso-C C-arm navigation in craniocervical surgery: the first 60 cases. *Neurosurgery* **54**:1131–1137, 2004
- Kado DM, Browner WS, Palermo L, et al: Vertebral fractures and mortality in older women: a prospective study. Study of Osteoporotic Fractures Research Group. *Arch Intern Med* **159**:1215–1220, 1999
- Kallmes DF, Schweickert PA, Marx WF, et al: Vertebroplasty in the mid- and upper thoracic spine. *AJNR* **23**:1117–1120, 2002
- Ledlie JT, Renfro M: Balloon kyphoplasty: one-year outcomes in vertebral body height restoration, chronic pain, and activity levels. *J Neurosurg Spine* **98**:36–42, 2003
- Lieberman IH, Dudeney S, Reinhardt MK, et al: Initial outcome and efficacy of “kyphoplasty” in the treatment of painful osteoporotic vertebral compression fractures. *Spine* **26**:1631–1638, 2001
- Linsenmaier U, Rock C, Euler E, et al: Three-dimensional CT with a modified C-arm image intensifier: feasibility. *Radiology* **224**:286–292, 2002
- Phillips FM, Ho E, Campbell-Hupp M, et al: Early radiographic and clinical results of balloon kyphoplasty for the treatment of osteoporotic vertebral compression fractures. *Spine* **28**:2260–2267, 2003

Intraoperative 3D fluoroscopy-based CT guidance for kyphoplasty

22. Rhyne A III, Banit D, Laxer E, et al: Kyphoplasty: report of eighty-two thoracolumbar osteoporotic vertebral fractures. **J Orthop Trauma** **18**:294–299, 2004
23. Rock C, Linsenmaier U, Brandl R, et al: [Introduction of a new mobile C-arm/CT combination equipment (ISO-C-3D). Initial results of 3-d sectional imaging.] **Unfallchirurg** **104**:827–833, 2001 (Ger)
24. Theodorou DJ, Theodorou SJ, Duncan TD, et al: Percutaneous balloon kyphoplasty for the correction of spinal deformity in painful vertebral body compression fractures. **Clin Imaging** **26**:1–5, 2002
25. Watts NB, Harris ST, Genant HK: Treatment of painful osteoporotic vertebral fractures with percutaneous vertebroplasty or kyphoplasty. **Osteoporos Int** **12**:429–437, 2001
26. Weisskopf M, Herlein S, Birnbaum K, et al: [Kyphoplasty-

a new minimally invasive treatment for repositioning and stabilising vertebral bodies.] **Z Orthop Ihre Grenzgeb** **141**: 406–411, 2003 (Ger)

Disclaimer

We did not receive funding, grants, services, or materials from any organization or company for this work. We do not have any personal or institutional financial interest in materials or devices described in this paper.

Manuscript received January 12, 2005.

Accepted in final form February 24, 2005.

Address reprint requests to: Alan T. Villavicencio, M.D., Boulder Neurosurgical Associates, 1155 Alpine Avenue, Suite 320, Boulder, Colorado 80304. email: atv@bnasurg.com.